



Arch. Bas. App. Med. 9 (2021): 45– 57

[www.archivesbamui.com](http://www.archivesbamui.com)

[www.ojshostng.com/index.php/abam](http://www.ojshostng.com/index.php/abam)

Research Article

## Artesunate, with or without Mefloquine, alters activities of Mast cells, Anti-inflammatory markers and Antioxidants in Rats with Acetic acid induced Gastric ulcers.

Salami A.T., Odukanmi A.O., Adeola A., Iyiola T.O. and \*Olaleye S.B

Gastrointestinal secretion and Inflammatory Research Unit,

Department of Physiology, Faculty of Basic Medical Sciences, University of Ibadan. Ibadan, Nigeria.

### Abstract

Artemisinin-based antimalarial drugs have previously been shown to enhance healing of experimental gastric ulcers when compared with the delayed healing effect of the chloroquine and its derivatives. During inflammatory phase of gastric ulcer healing, mast cells maintain the gastric epithelium's integrity. In this study the effects of some artemisinin-based antimalarial drugs on mast cells, anti-inflammatory markers and antioxidants activities during gastric ulcer healing was investigated. Male Wistar rats (140-170g, n=10) were divided into 5 groups. The control rats (Group 1) received normal saline and no ulcer was induced while in other groups, chronic gastric ulcers were induced using 60% acetic acid and treated accordingly for 7 days with normal saline (Group 2), Artesunate, 2mg/kg (Group 3), Artequine, 4mg/kg (Group 4) and Zinc sulphate, 80mg/kg (Group 5). Bodyweight, haematological variables, ulcer score, gastric biochemical and histological analysis were assessed 3- and 7-days post ulceration. Data were analyzed using One-way ANOVA and Dunnett post-hoc tests at  $p < 0.05$ . Reduction in body weight was observed in animals 3 and 5 days after ulcer induction, though there was significant reversal of weight losses above the pre-ulcer values by day 7. Healing was evident in the stomach of all animals with acetic acid-induced ulcers. By day-7, the mean ulcer score in the normal saline-, Artequine- and Zinc sulphate-treated rats were  $8.40 \pm 0.35$ ,  $0.27 \pm 0.27$  and  $0.33 \pm 0.17$  respectively. No visible ulcers were seen in the Artesunate treated group (100% healing rate). Neutrophil/lymphocyte ratio and gastric nitrite levels were significantly increased in the normal saline treated group 3 days after ulcer induction. Platelet count was significantly increased in the antimalarial treated groups compared with the untreated group. Platelet/nitric oxide levels were reduced in the saline treated ulcerated group on both days 3 and 7. Gastric hydrogen peroxide levels significantly increased in the treatment groups compared with control group. Gastric sulfhydryl level was significantly increased in the artesunate treated, ulcerated group compared with other groups. The degranulated mast cells significantly increased in the zinc and artequine groups by both days 3 and 7 after ulcer induction compared with other groups. Artemisinin based-combination drug enhanced healing of experimental chronic gastric ulcer healing through regulated activities of mast cells, blood inflammatory biomarkers and endogenous anti-oxidative mechanisms.

**Key Words:** Gastric ulcer, Antimalarial, Mast cells, endogenous anti-oxidants, acetic acid.

### INTRODUCTION

Gastric ulcers are deep defects penetrating through the *muscularis mucosa* as a result of overwhelming activities of aggressive factors militating against the gastric mucosa integrity (Werther, 2000, Tarnawski, 2005). Its summative classification with a duodenal ulcer is known as peptic ulcer disease (PUD). The prevalence of PUD is reducing globally with 141.9 per 100,000 persons year presenting either with or without complications (Azhari *et al.* 2018). The prevalence is now reduced in Sub-sahara Africa in a recent report from Nigeria (Zibima *et al.*, 2020), as against the high prevalence reported a few decades ago (Amure and Elegbe, 1975). Although the risk factors for PUD are still enormously high in the region especially with indiscriminate use of non-steroidal anti-inflammatory drugs (NSAIDs) and poor diagnostic index

for PUD, the endemicity of malaria infection in the already burdened region (Olliaro and Taylor, 2005; White, 2004), could be overwhelming.

Exposure of the gastric mucosa to any damaging agent causes intensive injury with loss of surface epithelium and denudation of *lamina propria* (Okita *et al.*, 1991). This causes an immunoregulatory and or immunologic cascade (Komi *et al.*, 2020) involving both blood and mast cells (Ng, 2010, Qu *et al.*, 1998). The gastric epithelium homeostasis is maintained by the activities and secretions from several cells inherent within it. One of such cells is the mast cells (Krystel-whittemore *et al.*, 2016, Douaiher *et al.*, 2014) that have been considered a major gastric mucosa inflammatory cell (Biernacka *et al.*, 2000). They are known to play important role in the various stages of gastric ulcer healing (Weller *et al.*,

\*Author for Correspondence: Tel: +234-8023255893

E-mail: [sbolaleye@yahoo.com](mailto:sbolaleye@yahoo.com)

2006, Salami *et al.*, 2020, 2021) especially the inflammatory, proliferative, and angiogenesis phases (Uspenskiĭ and Grinevich 1980; Dong *et al.*, 2020). Mast cells release their contents histamine (Gschwandtner *et al.*, 2008), serotonin (Maekawa *et al.*, 2002; Mekori and Galli 1990), vascular endothelial growth factor (VEGF) (Dong *et al.*, 2020) with a controlled accumulation of neutrophils in the gastric mucosa (Chow *et al.*, 1998) necessary for gastric ulcer healing. The released histamine, tryptase, VEGF, and serotonin have been documented to be beneficial for wound contraction when in minute quantity (Klymenko *et al.*, 2000). The release of reactive oxygen species in varying quantities following exposure to toxicants has been implicated also in the healing processes of stomach ulcer and have been a major cause of a decline in the role of antioxidants which are gastroprotective (Suzuki *et al.*, 2012).

Among these mucosa damaging agents, the stomach is exposed to is the barrage of medications implored in the treatment of malaria in these endemic regions among which are Chloroquine phosphate, Quinine, Artesunate, Coartem, Artequin, and Mefloquine. Although some of these medications have been protective of the existing gastric ulcerations, few others have adversely affected its healing. Chloroquine phosphate, one of the earliest antimalarial (Greenwood, 1995 and WHO, 2008), has been reported to potentiate gastric ulceration in experimental rats via increased gastric acid secretion (Etimita *et al.*, 2005, Ajeigbe *et al.*, 2008; Olaleye and Ajeigbe, 2009, Salami *et al.*, 2016). Quinine was reported to have delayed ulcer healing by prolonging the inflammatory phase of healing, increasing oxidative stress, reducing antioxidant activity and gastric mucus secretion (Adeniyi *et al.*, 2017). On the other hand, Artesunate; a semi-synthetic derivative of artemisinin, generally well-tolerated and safe (Arnold *et al.*, 1990; Cao *et al.*, 1997; Ha *et al.*, 1997), has been reported to decrease gastric acid secretions and total acidity in a dose-dependent manner (Price, 2000). Artequin, an Artemisinin-based combination therapy (ACT) drug, is the combination of Artesunate and Mefloquine. Artemisinin is currently the most rapidly acting and potent antimalarial (Nosten *et al.*, 2000); and it has been documented to ameliorate gastric ulcers in experimental rats (Ajeigbe *et al.*, 2008, Ajeigbe *et al.*, 2018). This study further investigates the impact of ACTs; Artequin and Artesunate therapies on early gastric ulcer in adult male

Wistar rats with a focus on the role played by mast cells, inflammatory cells, and antioxidants in the healing pathway.

**MATERIALS AND METHODS**

**Experimental Animals:** Fifty (50) healthy male Wistar strain rats of comparable weights (140-170g) were used for this study. They were housed in solid bottom polypropylene cages under standard environmental conditions at the Central Animal House, College of Medicine, University of Ibadan. The animals were fed with standard commercial pellets (Ladokun feeds Nigeria Limited, Ibadan, Nigeria) and given clean tap water *ad libitum*.

**Drug Treatment and Animal Groups:** The animals were divided into five groups (n=10) as shown in Fig.1. Group 6 = Ulcerated treated Zinc (Gastric ulcer induced + Zinc sulphate treatment; 80mg/kg).

**Drug Administration**

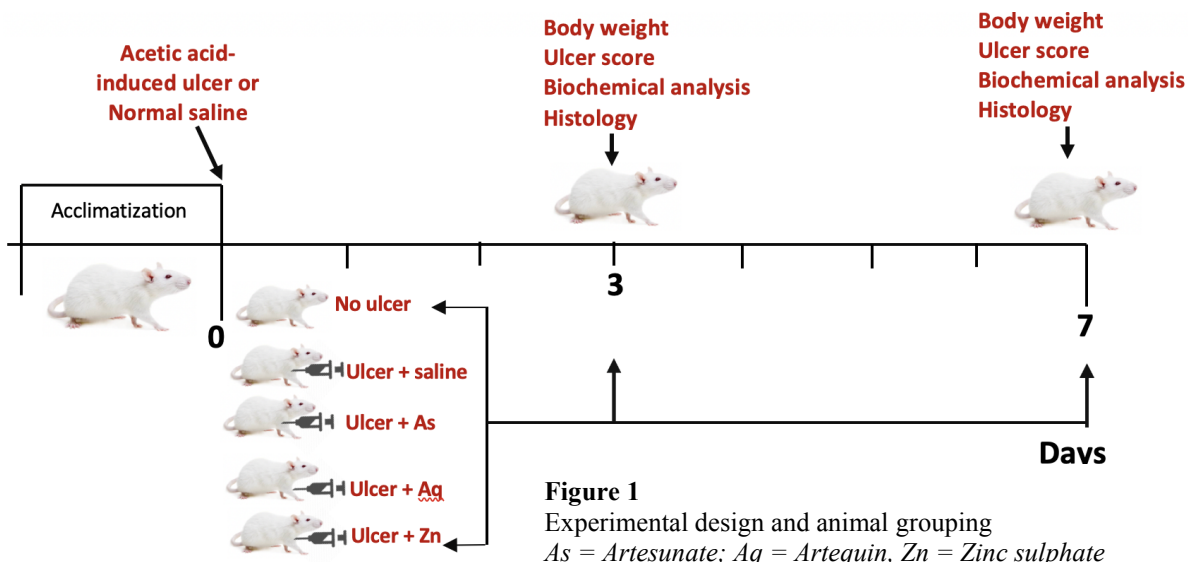
**Artesunate:** Artesunate (2 mg/kg b.w) was purchased from Mekophar Chemical Pharmaceutical joint company, Chi Minh city-Vietnam.

**Artequin:** Artequin (5 mg/kg mefloquine; 4 mg/kg artesunate) was purchased from AcinoPharma, Switzerland.

**Zinc:** Zinc (80 mg/kg b.w) was administered in form of Zinc sulphate (ZnS) was manufactured by Chi Pharmaceutical Ltd, Chivita Avenue Ajao Estate, Isolo, Lagos, Nigeria.

All drugs were administered orally using an oesophageal cannula according to Olaleye and Elegbe (2005).

**Experimental gastric ulcers:** Animals were acclimatized for two weeks. Chronic gastric ulcer was induced by acetic acid according to the method of Okabe *et al.*, (2010) and with little modification as in Salami *et al.* (2015). Briefly, 60% acetic acid was injected into the sub-serosal layer in the glandular part of the antra wall of 24 hours fasted rats (but had access to clean drinking water) (Salami *et al.*, 2014). This was later removed using a 1ml syringe after which the stomach or gastric serosa was washed gently with normal saline. The abdomen was sutured back and the animals were placed in their cages after recovery with free access to air and water. The various treatments commenced after three days of gastric ulcer induction and lasted for seven days.



**Sample collections:** Changes in body weights were recorded, blood samples were collected via retro-orbital puncture with the aid of micro haematocrit capillary into an ethylene-diamine-tetra-acetic acid (EDTA) bottle for determination of haematological parameters by days 3 and 7 of treatments according to the method of Dacies and Lewis (1994).

Five (5) animals were randomly selected per group on days 3 and 7 of treatments respectively. The animals were sacrificed by cervical dislocation (Eboh *et al.*, 2015). An incision was made along the midline at the *linea alba* of the ventral part, the liver was harvested and weighed while the stomach was collected and cleared of adherent tissues and weighed immediately with an electronic weighing scale, (model DT 1000 with a capacity of 0.1 to 1000g). The ulcerated part of the stomach was then minced with scissors into two sections:

A section was stored in 10 volumes of ice-cold 0.1M phosphate buffer, pH 7.4, and homogenized using a Teflon homogenizer. The resulting homogenate was centrifuged using a Kubota Hybrid Centrifuge at 10,000rpm, 4°C for 10minutes. The supernatant –post mitochondrial fraction (PMF) was collected and processed for biochemical estimations.

The other section was fixed up in 10% phosphate buffer formalin for histological evaluation (Hematoxylin and Eosin staining as described by Avwioro, 2002) and special staining for mast cells (Toluidine blue) as described by Luna (1968) and Crookham and Dapson (1991),

#### Ulcer scoring

Scoring of the gastric ulcerated area was done after opening from the greater curvature and bathed in normal saline, spread out with pins on a soft cork board and then photographed. The ulcerated area (mm<sup>2</sup>) was calculated using the collection guiding principles of Drug administration of Ministry of Health Beijing, 1993, using the equation:

$$S = \pi (d_1/2) \times (d_2/2).$$

(Where S represents the ulcerated area (mm<sup>2</sup>); d<sub>1</sub>: represents the longest longitudinal diameter of the ulcer, d<sub>2</sub> represents the longest transverse diameter of the ulcer).

The percentage (%) of ulcer healing was obtained according to Onasanwo *et al.*, 2010, Salami *et al.*, 2018 using the following formula:

$$\text{Percentage (\%)} = \frac{U_C - U_X}{U_C} \times 100$$

(Where U is the percentage of animals in the group with ulcer; U<sub>C</sub> is the Control mean ulcer index and U<sub>X</sub> is the mean ulcer index of the test group).

#### Biochemical Analysis

**Protein Concentration:** The gastric tissue protein concentration was measured using the Biuret method according to Gornal *et al.*, (1949), but there was a slight adjustment to the method as potassium was added to the reagent to prevent precipitation of Cu<sup>2+</sup> ions as cuprous oxide (Salami *et al.*, 2020).

**Oxidative stress Assessment:** This form of assessment is also known as Lipid peroxidation (MDA) assessment. It was determined by measuring the thiobarbituric acid reactive substances (TBAR) produced during lipid peroxidation. This was carried out using the method of Varshney and Kale, (1990).

**Determination of Mucosal Nitrite Concentration:** Tissue levels of NO was quantified indirectly as total nitrite (NO<sub>2</sub>) using Griess reagent of which the reaction relies on diazotization with sulfanilic acid and N-1-naphthyl-ethylene diamine to give a coloured product that can be read at 548nm (Ignarro *et al.*, 1987, Omayone *et al* 2016).

**Determination of Sulphydryl Content:** Sulphydryl content was assayed according to the method of Ellman, 1959.

**Determination of Hydrogen Peroxide:** Hydrogen peroxide was determined according to the method of Wolff *et al.*, 1994, Salami *et al.*, 2018

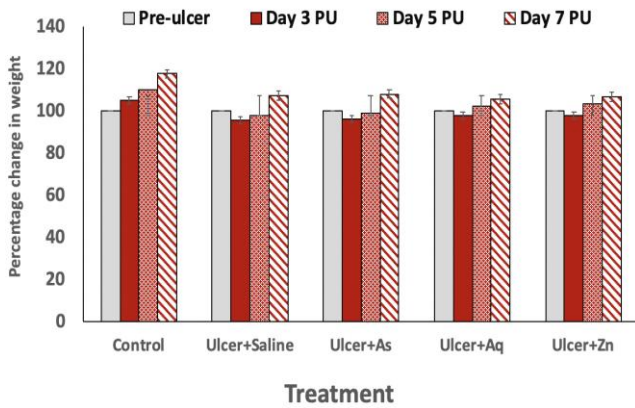
**Histological technique for Mast cell Stain:**—Cut stomach tissues were fixed in 10% phosphate buffered formalin then embedded in paraffin wax which were then sectioned onto a slide, de-paraffinized, stained with Harris hematoxylin, dipped in lithium carbonate before staining with toluidine blue (Luna 1968). The sections were in the toluidine stain for 30 minutes thereafter rinsed with water for 7-10 minutes and dehydrated before mounting back. The mast cells (Ribatti 2018, Ribatti and Crivellato, 2012) were counted as described by Strobel *et al.*, (1981).

**Statistical analysis:** The Mean, Standard Deviation and Standard Error of Mean were calculated. The results were expressed as Mean ± SEM. One-way ANOVA was used to analyze the differences among them. Comparisons between the two groups were done using student's t-test. The statistical difference was taken to be significant at p<0.05.

## RESULTS

**Effect of Artesunate, Artequine and Zinc sulphate on percentage (%) Body Weight in Acetic Acid induced ulcerated rats:** Figure 2 shows the effect of Artesunate and Artequine treatments on the percentage body weight of rats with acetic acid-induced ulcers three, five and seven days after treatments with antimalaria drugs. For the control (intact) animals, body weight did not show any decline, but increased steadily by 4.85%, 9.88% and 17.55% by days 3, 5 and 7 respectively. There were significant reductions in body weights of all animals that had experimental ulcers three days post ulcer induction. However, significant recoveries were observed in the percentage body weights of all the animals seven days post ulcer and treatments.

**Ulcer score and Percentage healing rates :** Plate 1 shows the representative gross stomach samples for each group, gastric ulcer scores and percentage healing rates seven days after treatments with Artesunate, Artequine and Zinc sulphate. Three days post-treatment, a mean ulcer score of 78.87± 5.21 was recorded in the untreated control was significantly higher than scores for the Artesunate- (13.33 ± 2.94), Artequine- (5.23 ± 0.33) and Zinc sulphate- (1.82 ± 0.34) treated groups. (in Acetic Acid induced ulcerated rats. By day-7, the mean ulcer score in the normal saline-, Artequine- and Zinc sulphate-treated rats were 8.40 ± 0.35, 0.27± 0.27 and 0.33 ± 0.17 respectively. No visible ulcers were seen in the Artesunate treated group (100% healing rate).

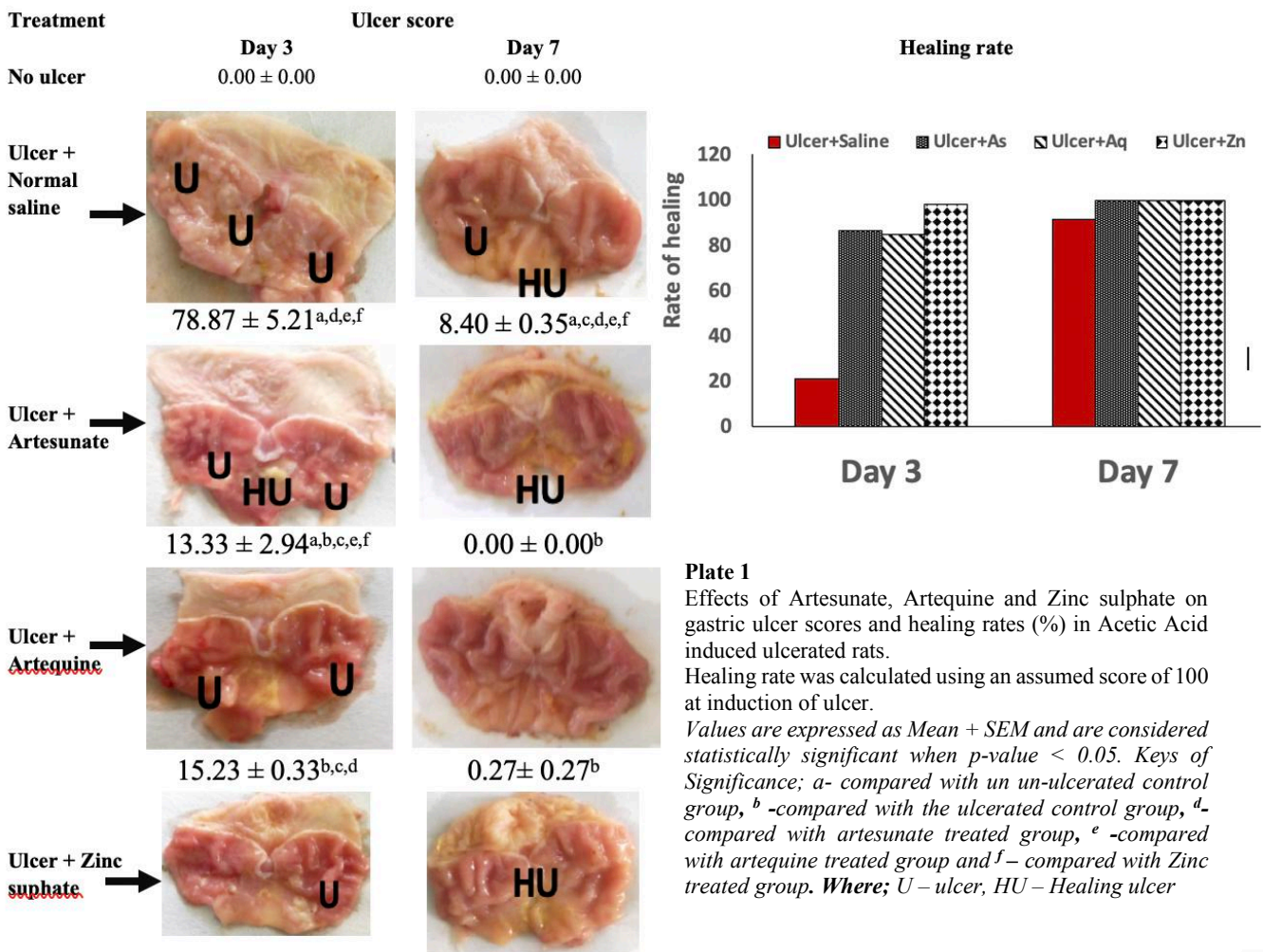


**Figure 2:** Body weight changes in Control and Ulcerated rats before and after treatments with Artesunate and Artequine and Zinc sulphate. Each bar represents percentage change over pre-ulcer values for each group  
 Keys: As = Artesunate; Aq = Artequine; Zn = Zinc sulphate

**Ulcer score and Percentage healing rates :** Plate 1 shows the representative gross stomach samples for each group, gastric

ulcer scores and percentage healing rates seven days after treatments with Artesunate, Artequine and Zinc sulphate. Three days post-treatment, a mean ulcer score of  $78.87 \pm 5.21$  was recorded in the untreated control was significantly higher than scores for the Artesunate- ( $13.33 \pm 2.94$ ), Artequine- ( $5.23 \pm 0.33$ ) and Zinc sulphate- ( $1.82 \pm 0.34$ ) treated groups. (in Acetic Acid induced ulcerated rats. By day-7, the mean ulcer score in the normal saline-, Artequine- and Zinc sulphate-treated rats were  $8.40 \pm 0.35$ ,  $0.27 \pm 0.27$  and  $0.33 \pm 0.17$  respectively. No visible ulcers were seen in the Artesunate treated group (100% healing rate).

**Red blood cell indices and ESR:** Table 2 shows the effect of Artesunate and Artequine treatments on Red blood cell indices and ESR of acetic acid Induced Ulcerated Rats by days 3 and 7. There was a decrease in MCHC in the artesunate and artequin treated groups compared with the untreated group on day 3 but was decreased in Zinc treated group on both days 3 and 7. The level of ESR was significantly decreased ( $p < 0.05$ ) by day 3 in the chloroquine and artequin treated groups when compared with the untreated and zinc treated groups. The MCV and MCH were not significantly different between groups irrespectively of the days.



**Plate 1** Effects of Artesunate, Artequine and Zinc sulphate on gastric ulcer scores and healing rates (%) in Acetic Acid induced ulcerated rats. Healing rate was calculated using an assumed score of 100 at induction of ulcer. Values are expressed as Mean + SEM and are considered statistically significant when  $p$ -value  $< 0.05$ . Keys of Significance; a- compared with un-ulcerated control group, b -compared with the ulcerated control group, d- compared with artesunate treated group, e -compared with artequine treated group and f – compared with Zinc treated group. **Where;** U – ulcer, HU – Healing ulcer

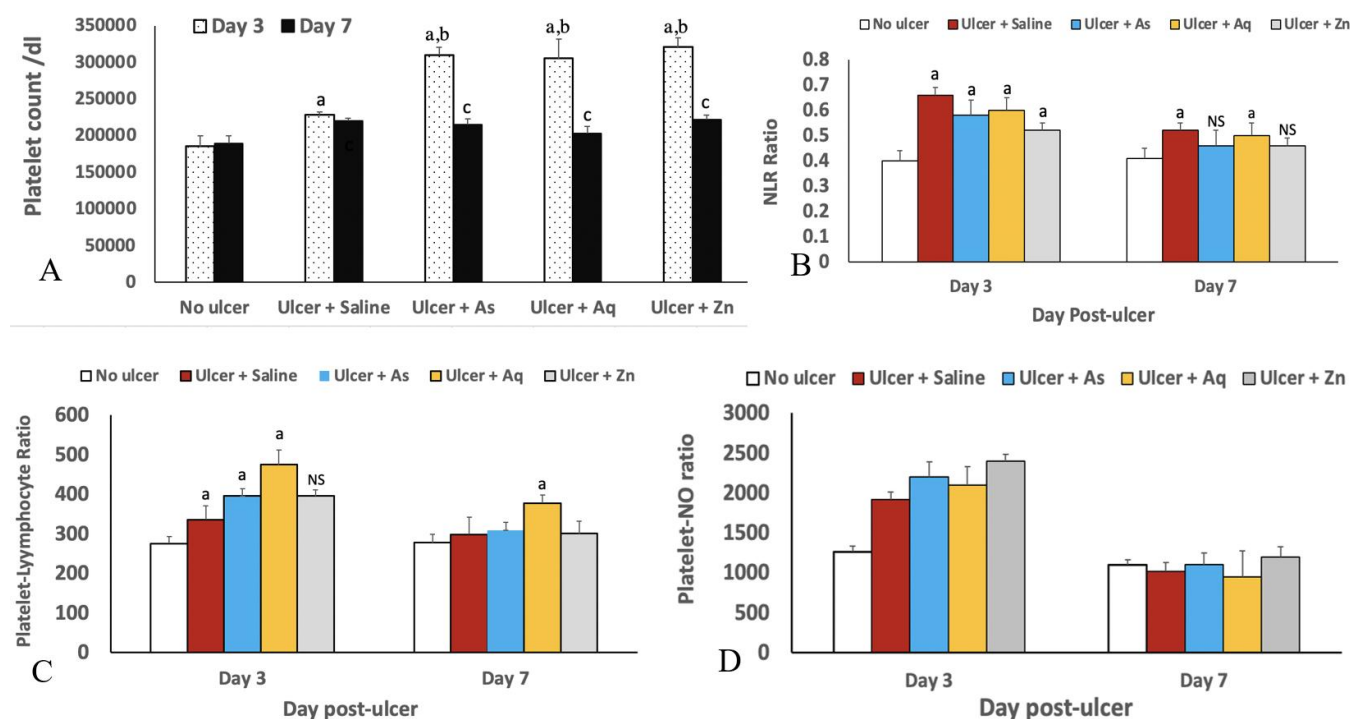
**Table 2:**

Effect of Effects of Artesunate, Artequine and Zinc sulphate on derived red blood cell indices and ESR of 3 and 7 days after experimental acetic Acid-Induced Ulceration

Group	MCV(fl)		MCHC(g/dl)		MCH(pg)		ESR (mm/h)	
	Day 3	Day 7	Day 3	Day 7	Day 3	Day 7	Day 3	Day 7
Control (No ulcer)	60.81 ± 1.568	60.36 ± 0.972	211.7 ± 3.01	206.6 ± 2.74	21.17 ± 0.301	20.66 ± 0.274	0.80 ± 0.054	0.82 ± 0.057
Ulcer + Saline	61.56 ± 0.402	58.9 ± 0.557	212.0 ± 11.31	197.4 ± 3.79	21.20 ± 1.131	19.74 ± 0.379	1.07 ± 0.067 <sup>e</sup>	1.06 ± 0.064
Ulcer +As	58.80 ± 0.800	57.28 ± 0.460	201.6 ± 0.65	195.8 ± 3.43	20.16 ± 0.065	19.58 ± 0.343	0.83 ± 0.088 <sup>f</sup>	0.90 ± 0.057
Ulcer +Aq	59.42 ± 0.982	59.02 ± 1.070	200.1 ± 3.35	209.3 ± 11.93	20.01 ± 0.335	20.93 ± 1.193	0.79 ± 0.033 <sup>b,f</sup>	0.87 ± 0.067
Ulcer +Zn	59.37 ± 0.875	57.21 ± 0.657	196.5 ± 3.40	189.3 ± 1.12	19.65 ± 0.340	18.93 ± 0.112	1.13 ± 0.067 <sup>a,d,e</sup>	1.07 ± 0.067

Values are expressed as Mean ± SEM and are considered statistically significant when p-value ≤ 0.05.

Keys of significance; <sup>a</sup> - compared with the un-ulcerated control group, <sup>b</sup> -compared with the ulcerated control group, <sup>d</sup>-compared with artesunate treated group, <sup>e</sup> -compared with artequine treated group and <sup>f</sup> – compared with Zinc treated groups.



**Figure 3:**

Effect Artesunate, Artequine and Zinc sulphate on platelet count and levels of blood inflammatory markers in Acetic acid-Induced ulcerated Rats by Days 3 and 7.

Values are expressed as Mean ± SEM and are considered statistically significant when p-value ≤ 0.05. Key: Neutrophil/Lymphocyte (N/L) Ratio, Platelet/Lymphocyte (P/L) Ratio and Platelet/Nitrite (P/NO) Ratio. <sup>a</sup> – significant when compared with the un-ulcerated control group on day 3. <sup>c</sup> -significant when compared with the ulcerated control group on day 7.

**Blood inflammatory markers (Neutrophil/Lymphocyte (N/L) Ratio, Platelet/Lymphocyte (P/L) Ratio and Platelet/Nitrite (P/NO) Ratio) in acetic acid-Induced Ulcerated Rats:** Figure 3 shows the effect of Artesunate and Artequine treatments on blood inflammatory markers in acetic acid-induced Ulcerated Rats by Days 3 and 7. Neutrophil/lymphocyte ratio significantly increased in the untreated group by day 3 but significantly decreased by day 7 compared with the control and the treated groups. Platelet/lymphocyte ratio was significantly reduced in the control, untreated, and artesunate treated groups compared

with the artequine treated group by day 3. By day 7, the zinc treated group had a significantly increased platelet/lymphocyte count compared with all other groups. The Platelet/nitrite level was significantly decreased in the untreated group compared with all other groups by day 3 while the zinc treated group had significantly increased Platelet/nitrite level by day 7 compared with all other groups

**Gastric protein, MDA and NO levels in Acetic Acid-Induced Ulcerated Rats:** Gastric protein level in the rats without ulcer on day 3 post-ulcer was 0.54 ± 0.03mg/dl. In

the rats with gastric ulcers, protein levels were significantly reduced ( $0.27 \pm 0.01$ mg/dl,  $0.37 \pm 0.001$ mg/dl and  $0.27 \pm 0.02$  mg/dl for Artesunate, Artequine and Zinc sulphate groups respectively). Similar patterns were observed on day 7. (Table 3). Gastric MDA level in the rats without ulcer on day 3 post-ulcer was  $0.57 \pm 0.002 \times 10^{-5}$ µMol/mg protein. In the rats with gastric ulcers, MDA levels were significantly increased ( $1.203 \pm 0.03 \times 10^{-5}$ ,  $1.947 \pm 0.18 \times 10^{-5}$ ,  $2.730 \pm 0.21 \times 10^{-5}$  and  $0.850 \pm 0.07 \times 10^{-5}$  µMol/mg protein for Artesunate, Artequine and Zinc sulphate groups respectively). Similar patterns were observed for MDA levels on day 7. The gastric nitrite level was also significantly increased in the ulcer induced rats 3 and 7 days after treatments.

**Gastric Sulphydryl and Hydrogen peroxide (H<sub>2</sub>O<sub>2</sub>) content in Acetic acid-induced ulcerated rats:** Figure 4 shows the effect of Artesunate and Artequine treatments on gastric Sulphydryl and Hydrogen peroxide (H<sub>2</sub>O<sub>2</sub>) content in Acetic acid-induced ulcerated rats. By day 7, there was a significant increase in the sulphydryl levels in the ulcerated artesunate and artequine treated groups when compared with the ulcer untreated, and zinc treated groups. There was a significant decrease in the hydrogen peroxide level of the ulcerated untreated group compared with the ulcerated zinc, and artesunate treated groups by day 3 post ulceration while no significant level was observed between all the experimental groups by day 7 post ulceration.

**Gastric mucosa mast cells population:** Figure 5 shows the effect of Artesunate and Artequine treatments on gastric mucosa mast cells population. The control, untreated and zinc treated groups had more intact mast cells compared to the Artesunate and Artequine treated groups by days 3 and 7. Degranulated mast cells were however higher in the Artesunate and Artequine treated groups compared to other groups by days 3 and 7 of treatments.

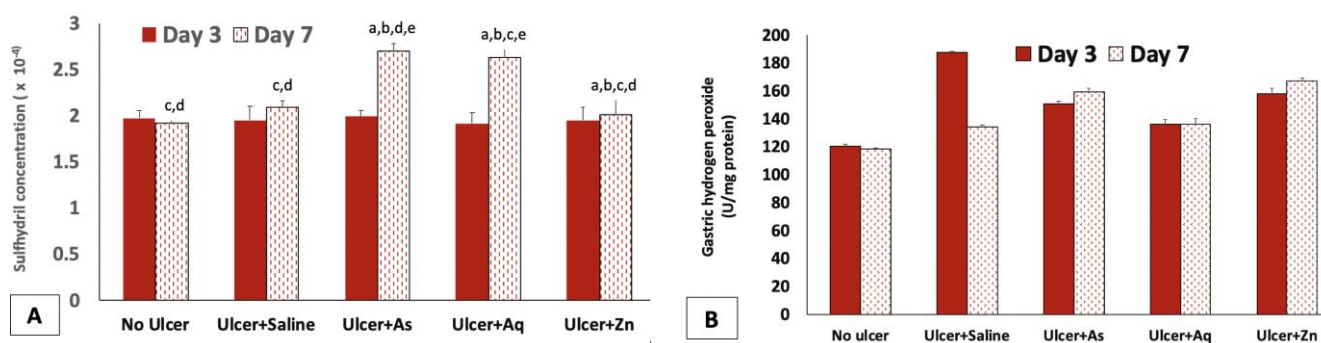
Plate 2 shows the effect of Artesunate and Artequine treatments on histology of gastric mucosa mast cells population. By day 3 there were very scanty mast cells (MtC) in the submucosa in the control while the untreated group presented a marked absence of mast cells in the area of ulceration and very scanty mast cells in other foci. However, the Artequine and Zinc treated groups showed the mild presence of mast cells in the area of oedema, submucosa and muscularis while the Artesunate treated group showed scanty mast cells in the submucosa. By the 7<sup>th</sup> day of treatment, there were scanty mast cells (MtC) in the submucosa in the control but the untreated presented very scanty mast cells in the submucosa. However, there was the moderate, mild and very scanty presence of mast cells in the submucosa area of the Artequine and Artesunate treated groups respectively. The Zinc treated showed a mild presence of fibroblasts lining the submucosa of the gastric tissue.

**Table 4:** Effect of Artesunate, Artequine and Zinc sulphate on gastric protein, MDA and NO levels in Acetic Acid-Induced Ulcerated Rats.

Groups	Protein (mg/mLs)		MDA (µMol/mg protein x 10 <sup>-5</sup> )		NO (Um/g tissue)	
	Day 3	Day 7	Day 3	Day 7	Day 3	Day 7
<b>Control (No ulcer)</b>	$0.54 \pm 0.03^{b,d,e}$	$0.56 \pm 0.043^{b,d,e,f}$	$0.57 \pm 0.002$	$0.493 \pm 0.017$	$77.72 \pm 10.75$	$57.03 \pm 1.388$
<b>Ulcer + Saline</b>	$0.27 \pm 0.01^{a,d}$	$0.30 \pm 0.017^a$	$1.203 \pm 0.03^a$	$1.117 \pm 0.019^a$	$107.5 \pm 0.51^{a,d,e}$	$109.9 \pm 2.89^a$
<b>Ulcer +As</b>	$0.37 \pm 0.001^{a,b,f}$	$0.34 \pm 0.002^a$	$1.947 \pm 0.18^{a,b}$	$1.553 \pm 0.077$	$83.90 \pm 1.63^{b,e,f}$	$95.06 \pm 5.97$
<b>Ulcer+Aq</b>	$0.34 \pm 0.01^{a,b,f}$	$0.39 \pm 0.03^a$	$2.730 \pm 0.21^{a,b}$	$1.710 \pm 0.068$	$81.33 \pm 5.60^{a,b,,f}$	$93.4 \pm 8.30$
<b>Ulcer+Zn</b>	$0.27 \pm 0.02^{a,d}$	$0.35 \pm 0.003^a$	$0.850 \pm 0.07^{a,b}$	$0.943 \pm 0.061$	$83.47 \pm 0.51^{b,e}$	$85.92 \pm 8.79$

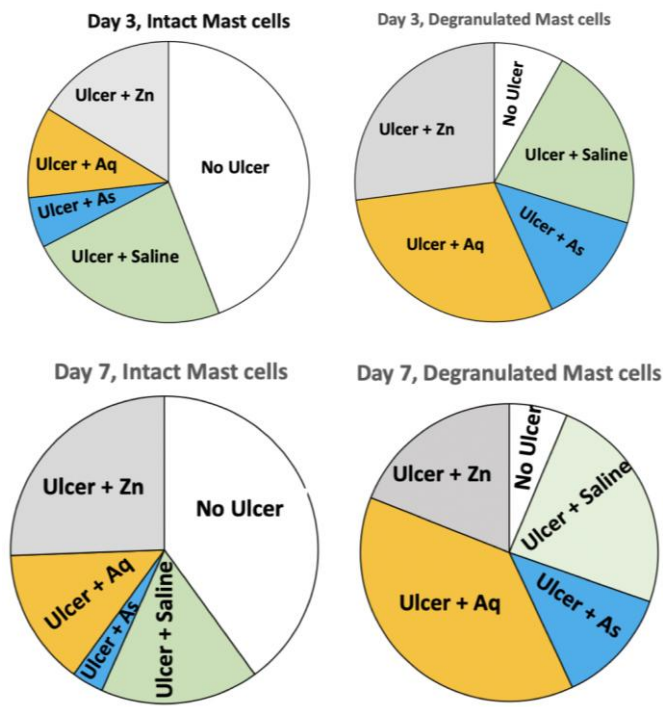
Values are expressed as Mean ± SEM and are considered statistically significant when p-value ≤ 0.05.

<sup>a</sup> - compared with the un-ulcerated control group, <sup>b</sup> -compared with the ulcerated control group, <sup>d</sup>-compared with artesunate treated group, <sup>e</sup>- compared with artequine treated group and <sup>f</sup>- compared with Zinc treated group.



**Figure 4.** Effect of Artesunate and Artequine treatments on gastric Sulphydryl and Hydrogen peroxide (H<sub>2</sub>O<sub>2</sub>) content in Acetic acid-induced ulcerated rats by Days 3 and 7.

Values are expressed as Mean ± SEM and are considered statistically significant when p-value ≤ 0.05. **Keys of significance;** <sup>a</sup> - compared with the un-ulcerated control group, <sup>b</sup> -compared with the ulcerated control group, <sup>d</sup>-compared with artesunate treated group, <sup>e</sup> -compared with artequine treated group and <sup>f</sup>- compared with Zinc treated group



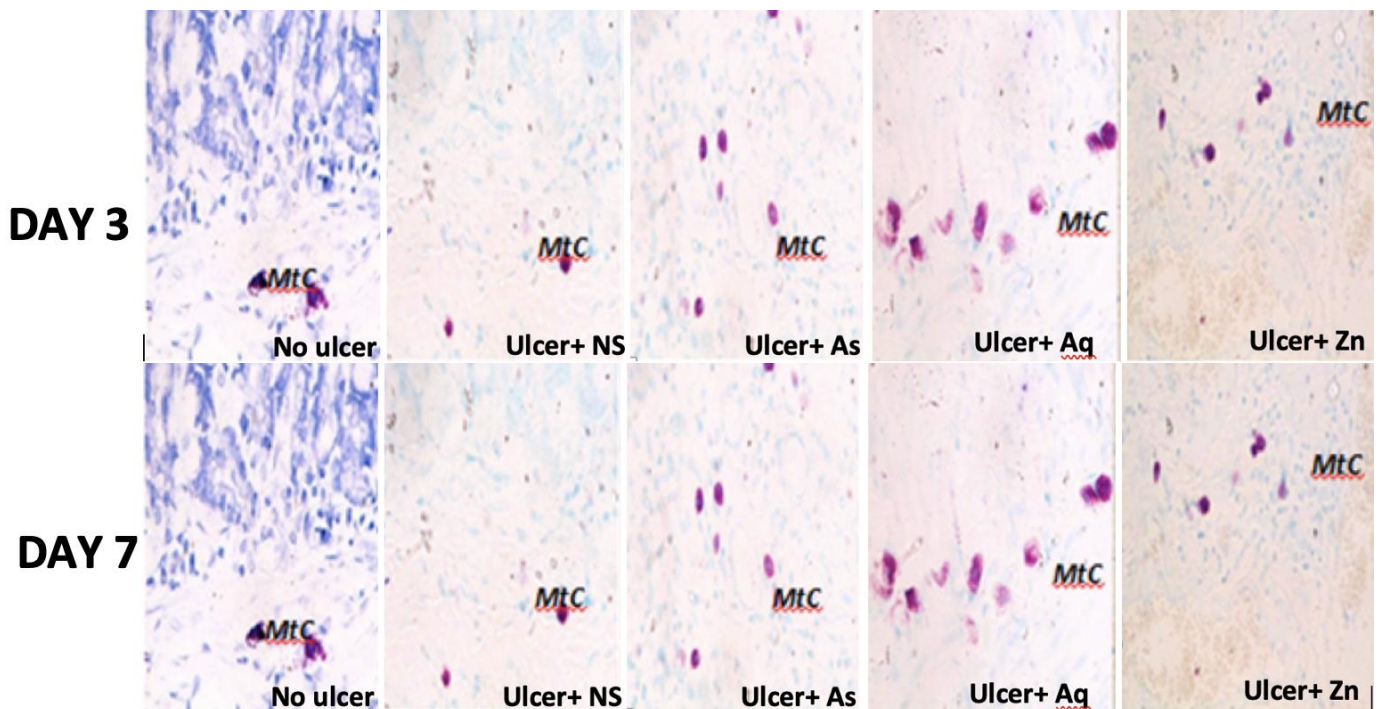
**Figure 4**  
Effect of Artesunate and Artequine treatments on gastric mucosa mast cells population.

**Gastric histological architecture in control and treated rats:** Plate 2 shows the effect of Artesunate and Artequine

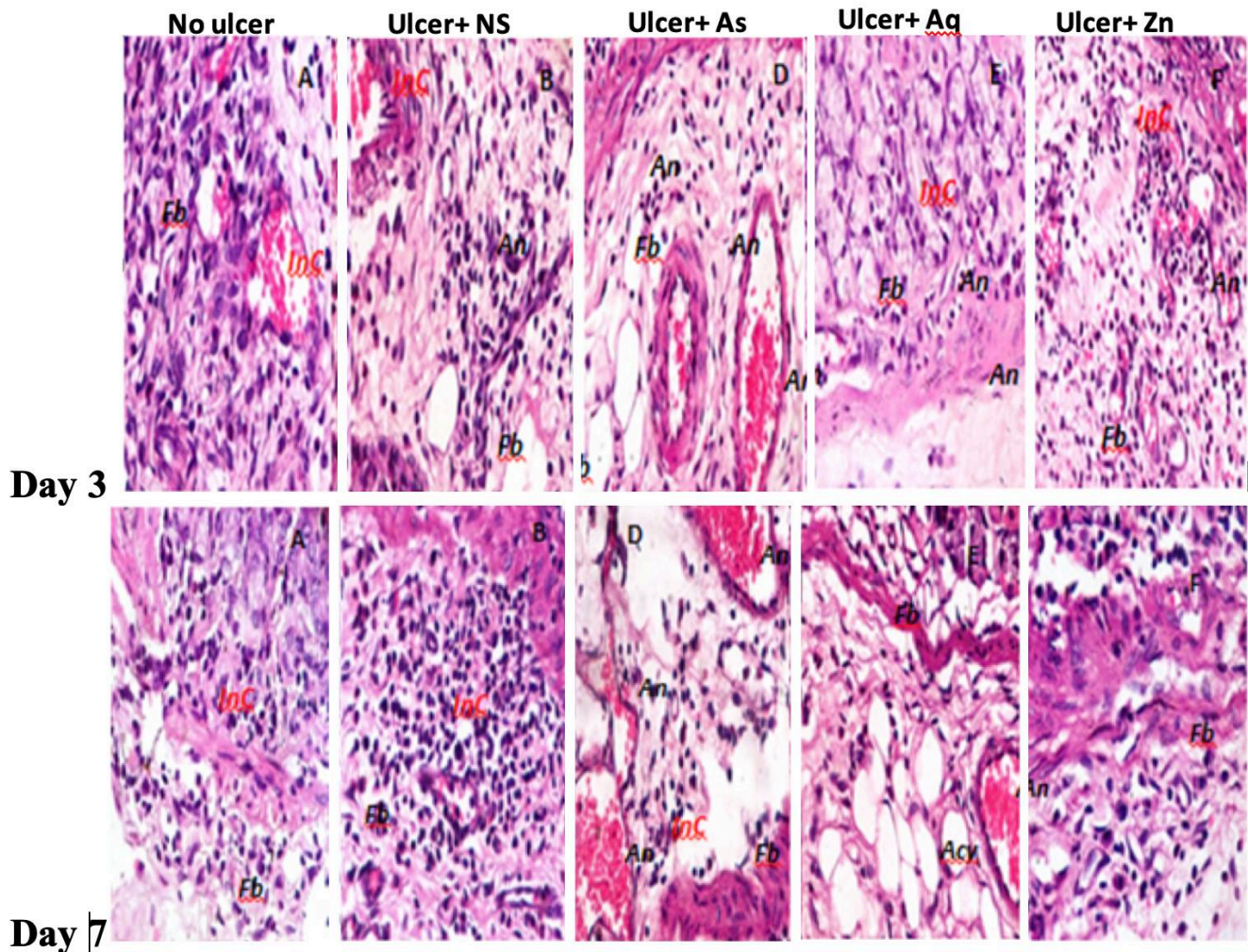
treatments on gastric histological architecture. By the 3<sup>rd</sup> day, there were normal mucosa, submucosa and muscularis and well-preserved surface epithelial in the control. The Ulcerated untreated group showed a focal area of ulceration (black arrow) with cellular debris, moderate angiogenesis (An), abundant fibroblast (Fb), moderate oedema (red arrow) and infiltration of inflammatory cells (InC).

The Artesunate treated group presented focal area of ulceration involving the mucosa, submucosa and muscularis with cellular debris, moderate angiogenesis (An) and abundant fibroblast (Fb), chronic inflammatory cells (InC) in the mucosa and submucosa and moderate angiogenesis (An) with congestion in the submucosa and abundant fibroblasts (Fb).

The Artequine treated rats presented focal area of ulceration involving the mucosa and submucosa, cellular debris, inflammatory cells (InC), moderate angiogenesis (An) and abundant fibroblast (Fb), mild papillary infolding, mild oedema (red arrow) with infiltration of inflammatory cells (InC) and mild adipocytes (Acy) while the ulcerated Zinc treated group showed multiple focal areas of ulceration (double arrow) involving the mucosa, submucosa and muscularis with cellular debris, moderate angiogenesis (An) and abundant fibroblast (Fb), moderate oedema (red arrow) with moderate infiltration of inflammatory cells (InC) and moderate angiogenesis (An) and abundant presence of fibroblasts (Fb). The observed histological alterations in day 3 were relatively milder or absent by day 7 in the treated groups as compared to the untreated group with a presence of abundant fibroblast (Fb) in the Artequine treated groups but mild in the zinc treated.



**Plate 2:**  
Effect of Artesunate and Artequine treatments on histological presentation of gastric mucosa mast cells population (Photomicrograph of stomach section with Toluidine blue stain, Mag x 400).  
NS = Normal saline; As = Artesunate; Aq = Artequine; Zn = Zinc; MtC = mast cells



**Plate 2:** Effect of Artesunate and Artequine treatments on gastric histological architecture (Photomicrograph of stomach section with H&E stain, Mag x 400). *An* =Angiogenesis, *Fb* = fibroblast, *InC* = inflammatory cells, *Acy*= Adipocytes.

**DISCUSSION**

Gastrointestinal ulcer affects people in all geographical regions and as such has become a global disease of public health significance. Generally, it is accepted that an imbalance between aggressive and mucosal integrity maintenance factors is what causes ulcers (Goel *et al.*, 1986). To regain the balance, different therapeutic agents have been used. The high prevalence of gastric ulcers in sub-Sahara Africa (Amure and Elegbe, 1975) couple with the menace of malaria infection (Olliaro and Taylor, 2005; White, 2004) indicate the use of antimalarial within the region during gastric ulceration. In the present study, the impact of some selected antimalarial drugs on gastric ulcer healing was investigated.

In the present study, acetic acid gastric ulcer induction causes a notable decrease in percentage body weight. In line with these findings, Malfertheiner *et al.* (2002) had reported gastric ulceration leads to loss of body weight. The findings in this study showed that artequine enhanced the decreased body weight observed after ulcer induction.

Both antimalarial drugs used in this study were observed to stimulate healing comparable with zinc treatment. In support of these findings, derivatives of artemisinin (which artesunate and artemether are an example) have been documented to have limited side effects and are generally safer (Price *et al.*, 2000) compared to the aminoquinolines (which quinine, chloroquine

and amodiaquine belong to) which are reported to be gastric mucosa aggressive and precipitate gastric ulceration (Ajeigbe *et al.*, 2008; Sha *et al.*, 2013). Kalange *et al.* (2020) had also reported that Artesunate confers protection against indomethacin-induced gastric ulcer.

Neutrophils are the major source of inflammatory mediators as they can release potent reactive oxygen species such as superoxide, hydrogen peroxidase and myeloperoxidase derived antioxidants (Cheng and Koo, 2000); which are highly cytotoxic and can induce tissue damage (Cheng and Koo, 2000). Neutrophil-to-lymphocyte ratio (NLR) has been used as a surrogate marker of systemic inflammation (Vatankhah *et al.*, 2017; Jafarzadeh *et al.*, 2013; Ajayi and Olaleye, 2020; Salami *et al.*, 2021). Increase in NLR is indicative of more inflammation, while a decrease suggests reduced inflammation, which gives rise to improved healing.

In the present study, platelet count was increased in the animals with experimental ulcers when compared with the control on day 3 post-ulcer. Platelets have been documented to also control inflammation and reduce the immune responses despite their haemostatic activity during disease conditions (Herter *et al.*, 2014, Stocker *et al.*, 2017). The observed platelet increase (day 3 post ulceration) might have enhanced the inflammatory phase of gastric ulcer healing in the present study as they act as modulators of inflammation (Kim *et al.*, 2017). Platelet contains a wide range of factors capable of



promoting tissue growth and new blood vessel formation (angiogenesis) including vascular endothelial growth factor (VEGF) (Linder *et al.*, 1979; Maloney *et al.*, 1998), transforming growth factor- $\beta$  and platelet factor-4 (Folkman *et al.*, 1991; Schmassmann *et al.*, 1995; Von Hundelshausen *et al.*, 2001). Probably, the facilitated gastric ulcer healing in the antimalarial treated groups might have been due to the deposition of various growth factors at the gastric ulcer sites (Ma *et al.* 2000) during the haemostatic phase of gastric ulcer healing. Platelet-Nitric oxide ratio (P/NO) is a marker of angiogenesis (Radziwon-Balicka *et al.*, 2012; Fukumura *et al.*, 2006, Fukumura *et al.*, 2001) and it was increased by day 3 but decreased by day 7 in the antimalarial treated groups. This observation indicates an increased nitric oxide level which is responsible for increased blood flow to the submucosa thus facilitating tissue oxygenation, nourishment to and probably angiogenesis at healing gastric ulcerated site (Seabra *et al.*, 2015).

Anti-malarial drugs such as chloroquine (Park *et al.*, 2004), artesunate (Anusha and Nirbhay, 2015) and ferroquine (Faustine *et al.*, 2008) acts by generating reactive oxygen species from its endoperoxide bond (Maggs *et al.*, 1998); leading to increased lipid peroxidation. In the present study, the Malondialdehyde (MDA) level of the antimalarial treated groups increased and this is following the observation by Ajeigbe *et al.* (2018). In the present study, gastric protein concentration was increase by day 3 but reduced by day 7 in the antimalarial treated groups which might have been due to earlier reports of increased protein catabolism during gastric ulcer (Segawa *et al.*, 1985). However, the increased MDA levels in the antimalarial treated groups, further demonstrates the action of antimalarial in inducing oxidative stress (Rio *et al.*, 2005, Giordano *et al.*, 2005) and might have also been responsible for the depleted protein levels in the antimalarial treated groups.

Studies have shown that cells maintain a variety of defences against oxygen toxicity and living system protect against oxidative damage by anti-oxidant enzymes and other endogenous anti-oxidant sources (Nilesh *et al.*, 2010). Sulfhydryl protein is an important antioxidant defence system against ulceration by binding to oxygen radicals (Salim, 1985) and contributes to protein synthesis (Turner *et al.*, 1977); thus, acting as agents that (may) repair minor breaches in the gastrointestinal mucosa as well as maintaining the mucosa integrity. In this study, artequine and artesunate enhanced gastric sulfhydryl compound evident in the repair of gastric mucosa damage (caused by ulceration) and probably facilitated healing unlike Chloroquine treated groups. This shared the same view with previous observations by Simon, (1961), who reported the inhibitory effect of chloroquine on sulfhydryl group reactivity.

Nitric oxide plays a vasodilatory role in gastric microcirculation during acid secretion (Pique *et al.*, 1987; 1992) and endothelial nitric oxide synthase (eNOS) –derived NO is the most important in terms of the healing process via angiogenesis (Lee *et al.*, 1999). Gastric nitrite level in the present study was decreased in all the antimalarial treated groups which probably reflected vasoconstriction and reduced blood flow to the ulcerated site.

Mast cells are crucial in wound healing and maintenance of the structural and functional integrity of the gastric epithelium (Nakayima *et al.*, 1996) as well as a rich source of inflammatory mediators such as histamine, proteoglycans, the

proteases tryptase and chymase, lipids, growth factors and cytokines (da Silver *et al.*, 2014). Many of these mediators have effects on cell growth, tissue turnover and repair. In chronic gastric ulcers, it has been reported that mast cells were numerous in the gastric mucosa and they are often in contact with the epithelial margin as detected immunohistochemically (Nakajima *et al.*, 1996). In an infected mucosa such as an ulcerated stomach, mast cells act in the inflammatory phase of gastric ulcer healing through the release of pre-stored mediators – histamine, serotonin, prostaglandins etc (Theoharides *et al.*, 2012).

However, the intensity of mast cell infiltration in gastric mucosa positively correlates with the intensity of neutrophil and mononuclear infiltration into ulcerated areas leading to inflammatory reaction modulated by platelets (Slaba *et al.*, 2015). The degranulated mast cell count (as shown in plate... gastric tissue histology) was increased in ulcerated artequine and chloroquine treated groups by days 3 and 7. This might have resulted in increased release of mast cell contents which probably facilitated gastric ulcer healing. One of the released contents of mast cells on degranulation is histamine which has been reported to facilitate angiogenesis (Norrby, 2002) through microvasculature permeability.

Prostaglandin (Ricciotti *et al.*, 2011) and platelet-activating factor (Krystel-Whittemore *et al.*, 2015) released from degranulated mast cell; enhances vascular permeability as well as Leukocyte cell adhesion which draws or attract neutrophils (Gaboury *et al.*, 1995) and platelets (Kubes and Kanwar 1994) towards the ulcerated site for increased healing. Degranulated mast cells activities at the ulcerated region might have been linked to or initiated by the increased platelet counts observed in these groups which modulated the excessive release of mast cell contents. Earlier it was observed that the gastric nitrite (nitric oxide) level in the ulcerated antimalarial treated groups was reduced, unlike the ulcerated untreated groups. For proper leukocyte cell adhesion to occur there has to be reduced venular blood flow (Panesh and Granger, 1998; Panesh *et al.*, 1999) to ensure a firm adhesive bond so that the produced leukocyte will be stationary. Reduced venular blood flow is partly achieved via reduced tissue nitric oxide availability (Arndt *et al.*, 1993) as occurred in the ulcerated antimalarial treated groups; these might have resulted in the increased white blood cells (leukocytes) and platelet counts (especially by day 3 post ulceration). These observations were ameliorated by day 7 in all the antimalarial treated groups where there was a reduced white blood cell count (especially neutrophils) and Platelet nitric oxide (P/NO) ratio but increased gastric nitrite levels (NO).

This observed inverse relationship especially at day 3 (reduced NO and increased platelet) in this study has been documented by Jin and Loscalzo (2010) in which NO has been stated to exert antiplatelet and antithrombotic activities. This inverse relationship might have accounted for the prevention of platelet-dependent thrombosis in the ulcerated antimalarial treated groups during gastric healing especially by day 3 post ulceration. Seales *et al.* (1999) and Thomas *et al.*, (2002) documented that while platelets are activated, there is increased generation of ROS notably H<sub>2</sub>O<sub>2</sub> (which act as a form of signal for platelet activation) but are checked by increased NO availability. A similar trend was observed in this study in which there were increased H<sub>2</sub>O<sub>2</sub> levels in the ulcerated untreated group but checked by the increase in NO in the same group by day 3 thus indicating controlled platelet

activation. This synergic relationship was also observed in the ulcerated chloroquine and zinc treated groups by day 7 post ulceration.

Histological evaluation from this study shows abundant fibroblast, moderate oedema, moderate infiltration of inflammatory cells into the submucosa and moderate angiogenesis in the submucosa of the ulcerated antimalarial treated groups unlike untreated groups with multiple foci of ulceration. These features might be as a result of the secreted components from degranulated mast cells such as Histamine, prostaglandins D<sub>2</sub> and leukotrienes (from leukocyte adhesion) which stimulates vasodilation (increased nitric oxide) resulting in gastric oedema (Serafin *et al.*, 1987) and fibroblast (Dave *et al.*, 2014) accumulation at the ulcerated site (Bradding *et al.*, 1992). Fibroblast enhance healing of ulcerated gastric ulcer (Konturek *et al.*, 1993) while promoting angiogenesis that supplies nutrients and oxygenation of newly formed gastric tissues Folkman *et al.*, 1992)

In conclusion, the findings of this study suggest that treatment with Artesunate and Artequine ameliorate gastric ulcer via stimulation of gastric sulfhydryl level, nitric oxide levels and in turn blood flow to the wound site for proper leukocyte adhesion by day 3. These reactions were reverted by day 7 via modulating oxidative stress (notably hydrogen peroxide a signal for platelet activation) to the barest minimal level during gastric ulcer healing.

## REFERENCES

- Adelusi, S.A., Salako L.A (1982). Tissues and blood concentrations of chloroquine administration in rat. *J. Pharm. Pharmacol.*, 354: 733-735.
- Adeniyi, O., Makinde, O., Friday, E., Olaleye, S.B (2017). Effects of quinine on gastric ulcer healing in Wistar rats. *Journal of Complementary and Integrative Medicine*, 14(4), 20160132. <https://doi.org/10.1515/jcim-2016-0132>
- Ajayi A.F and Olaleye S.B. (2020): Age-related changes in haematological parameters and biochemical markers of healing in the stomach of rats with acetic acid induced injury. *Toxicology Reports*, Vol 7; 1272-1281
- Ajeigbe, K.O., Nwobodo, E.O., Oyesola, T.O., Ofusori, D.A., Olaleye, S.B (2008). Chloroquine phosphate potentiates indomethacin and HCl/Ethanol-induced gastric mucosa injury in rats. *International Journal of Pharmacology*, 4(6): 482-486
- Ajeigbe K.O., Emikpe, B.O., Olaleye, S.B (2018). Effects of artemisinin, with or without lumefantrine and amodiaquine on gastric ulcer healing in rats: *Journal of Basic and Clinical Physiology and Pharmacology*. 29(5): 515-524. DOI: 10.1515/jbcp-2017-0145
- Amure and Elegbe R.A (1975). Acid gastric secretory response to histamine, crude porcine gastrin and pentagastrin in rats. *Gut*, 21(9): 324-326
- Anusha, M., Nirbhay, K (2015). Antimalarial action of Artesunate involves DNA damage mediated by Reactive oxygen species. *Antimicrobial agents and chemotherapy*. 59: 1
- Arndt H., Russell J.B., Kurose I., Kubes P., Granger D.N (1993). Mediators of leukocyte adhesion in rat mesenteric venules elicited by inhibition of nitric oxide synthesis. *Gastroenterology*. 105:675–680.
- Arnold, M., Barbul, A (2006). Nutrition and wound healing. *Plastic reconstruction surgery*. 117 (7 Suppl): 42s-58s
- Avwioro, O.G (2002). *Histochemistry and tissue pathology 1*. St. Claverianum press, Ibadan. Pp. 134-313.
- Azhari, H., Underwood, F., King, J., Coward, S., Shah, S., Ng, S., Ho, G., Chan, C., Tang, W., Kaplan, G. (2018). A36 The global incidence of peptic ulcer disease and its complications at the turn of the 21st century: a systematic review. *Journal of the Canadian Association of Gastroenterology*. 1(Suppl 2), 61–62. <https://doi.org/10.1093/jcag/gwy009.036>
- Biernacka D, Muszynski J, Tomaszewska A, Moskalewski S (2000). Relationship between mast cells/parietal cells and maximal/basal acid output ratio in chronic gastritis. *Res Exp Med (Berl)*. 200(1):35-41. PMID: 11197920.
- Bowman OD (2000): *Gastrointestinal Pathophysiology*. Faculty web pages.
- Cao, X.T (1997). Comparison of artemisinin suppositories, intramuscular artesunate and intravenous quinine for the treatment of severe childhood malaria. *Transactions of the Royal Soc Trop Med Hyg*. 91(3): 335-342.
- Cheng, C.L., Koo, M.W (2000). Effect of centella asiatica on ethanol induced gastric mucosa lesions in rats. *Life Sci*. 67: 2647-2653.
- Crookham, J., Dapson, R (1991). *Hazardous Chemicals in the Histopathology Laboratory*, 2nd ED, Anatech.
- Dacie, J.V. Lewis, S.M (1994). *Practical Haematology*, 7th edition. ELBS with Churchill Livingstone. Longman group UK. 5-82: 160-175
- da Silva, E.Z.M., Jamur, M.C., Oliver, C (2014). Mast Cell Function: A New Vision of an Old Cell. *Journal of Histochemistry & Cytochemistry*. 62(10): 698-738. doi:10.1369/0022155414545334
- Del Rio, D., Stewart, A.J., Pellegrini, N (2005). A review of recent studies on malondialdehyde as toxic molecule and biological marker of oxidative stress. *Nutr Metab Cardiovasc Dis*. 15(4): 316-28. doi: 10.1016/j.numecd.2005.05.003. PMID: 16054557.
- Dong, J., Chen, L., Zhang, Y., Jayaswal, N., Mezghani, I., Zhang, W., Veves, A (2020). Mast Cells in Diabetes and Diabetic wound healing. *Adv Ther*. 37(11):4519-4537. doi:10.1007/s12325-020-01499-4
- Douaiher, J., Succar, J., Lancerotto, L., Gurish, M. F., Orgill, D. P., Hamilton, M. J., Krilis, S. A., & Stevens, R. L (2014). Development of mast cells and importance of their tryptase and chymase serine proteases in inflammation and wound healing. *Advances in immunology*. 122: 211–252. <https://doi.org/10.1016/B978-0-12-800267-4.00006-7>
- Eboh, A.S, Ere, D., Chuku, L.C., Uwakwe, A.A (2015). Kolaviron an active biflavonoid of G. Kola prevents 1, 2 dimethylhydrazine induced oxidative initiation phase of colon carcinogenesis in wistar rats. *Journal of cancer and tumour international*. 2(2): 41-49
- Ellman, G.L (1959). Tissue Sulfhydryl groups. *Arch Biochem Biophys*. 82:70-7
- Etimita, Y.O., Bisong, S.A., Antai, A.B., Nku, C.O., Osim, E.E (2005). Preliminary studies on effect of Chloroquine phosphate on gastric acid secretion in rats. *Niger J. Physiol.Sci*. 20: 69-73
- Faustine, D., Khalife, J., Brocard, J., Dive, D., Biot, C (2008). Ferroquine, an indigenous anti-malarial drug- thoughts on the mechanism of action. *Molecules*. 13: 2900-2907.
- Folkman, J., Szabo, stovroff, M., Mcneil, N., Li, W. Shing, Y (1991). Duodenal ulcer. Discovery of a new mechanism and development of angiogenic therapy that accelerates healing. *Ann. Surg*. 241: 414-425.
- Fukumura, D., Kashiwagi, S., Jain, R.K (2006). The role of nitric oxide in tumour progression. *Nat Rev Cancer*. 6(7):521-34.
- Fukumura, D., Gohongi, T., Kadambi, A., Izumi, Y., Ang, J., Yun, C.O., Buerk, D.G., Huang, P.L., Jain, R.K (2001). Predominant role of endothelial nitric oxide synthase in vascular endothelial growth factor-induced angiogenesis and

- vascular permeability. *Proc Natl Acad Sci U S A.* 98(5): 2604-9.
- Gaboury, J.P., Johnston, B., Niu, X.F. Kubes, P. (1995). Mechanisms underlying acute mast cell-leukocyte rolling and adhesion in vivo. *J Immunol.* 154(2):804-13. PMID: 7814884.
- Gaboury, J.P., Johnston, B., Niu, X.F., Kubes, P. Mechanisms underlying acute mast cell-induced gastric H. pylori infection: success in both nude and euthymic mice. *Am. JGastroenterol.* 86: 1586- 1603
- Giordano, F.J (2005). Oxygen, oxidative stress, hypoxia and heart failure. *J Clin Inves.* 115:500-508
- Goel R.K., Saroj Gupta, R. Shankar, A.K. Sanyal, (1986), Anti-ulcerogenic effect of banana powder (*Musa sapientum* var. *paradisiaca*) and its effect on mucosal resistance. *Journal of Ethnopharmacology.* 18(1): 33-44.
- Gornall, A.G., Bardawill, C.J., David, M.M (1949). Determination of serum proteins by means of the biuret reaction. *J Biol Chem.* 177(2): 751-66. PMID: 18110453.
- Goldsmith, R.S (1995). Antiprotozoal Drugs. In: *Clinical Pharmacology*, Katzung, B.G. (Ed.). Prentice Hall, London, UK.,pp: 780-803.
- Greenwood, D (1995). Conflicts of interest: the genesis of synthetic antimalarial agents in peace and war. *J Antimicrob Chemother.* 36(5): 857-72. doi: 10.1093/jac/36.5.857. PMID: 8626269.
- Gschwandtner, M., Purwar, R., Wittmann, M. et al. (2008). Histamine up-regulates keratinocyte MMP-9 production via the histamine H1 receptor. *J Invest Dermatol.* 128:2783–91.
- Gordon, D.A., Klinkhoff, A.V. (2005). Major side effects of gold. Second line agents. In: *Harris ED*
- Ha, V (1997). Severe and complicated malaria treated with artemisinin, artesunate or artemether in Viet Nam. *Trans Roy Soc Trop Med Hyg.* 91(4):465-467.
- Herter, J.M., Rossaint, j. and Zarbock A (2014). Platelets in inflammation and immunity. *J Thromb Haemost.*; 12(11):1764-75.
- Hyun, M.Y., Sumagin, R., sarangi, P.P., Lomakina, E., Overstreet, M.G (2012). Uropod elongation is a common final step in leukocyte extravasation through inflamed vessels. *JEM.* 209:1349-1362
- Ignarro, L., Buga, G., Wood, K., Byrns, R. and Chaudhuri, G (1987). Endothelium derived relaxing factor produced and released from artery and vein is nitric oxide. *Proceedings of the national Academy of Sciences USA.* 84: 9265-9269
- Jafarzadeh A., V. Akbarpoor, V. Nabizadeh, M. Nemati, M.T. Rezayati (2013): Total leukocyte counts and neutrophil-lymphocyte count ratios among *Helicobacter pylori*-infected patients with peptic ulcers: independent of the bacterial status. *Southeast Asian J. Trop. Med. Public Health,* 44 (1) (2013), pp. 82-88
- Karita, M., Kouchiyama, T, Okita, K, and Nakazawa, T (1991). New small animal model for human gastric *Helicobacter pylori* infection: success in both nude and euthymic mice. *Am J Gastroenterol.* 86: 1596–1603.
- Khalid, A.G. Ali, J.A (2014). The protective role of camel's milk on some haematological parameters of male rats infected with gastric ulcer. *World journal of Pharmaceutical Sciences.* 2(11):1465-1468.
- Kim, S.J., Davis, R. and Jenne, C (2017). Platelets as Modulators of Inflammation. *Seminars in Thrombosis and Hemostasis.* 44(02): 091–101. doi:10.1055/s-0037-1607432 .
- Klymenko, M.O., Lupal'tsov, V.I., Iahniuk, A.I., Tatarko, S.V (2000). Vplyv serotoninu na zahoiuvannia eksperymental'noï vyrazky shlunka za umov vahotomiï [The effect of serotonin on the healing of an experimental stomach ulcer following vagotomy]. *Fiziol Zh.* 46(4):52-7. Ukrainian. PMID: 10997300.
- Komi, D.E.A., Khomtchouk, K., Santa Maria, P.L (2020). A Review of the Contribution of Mast Cells in Wound Healing: Involved Molecular and Cellular Mechanisms. *Clin Rev Allergy Immunol.* 58(3): 298-312. doi: 10.1007/s12016-019-08729-w. PMID: 30729428.
- Konturek, S.J., Piastucki, I., Brzozowski, T., Radecki, T., Dembinska-Kiec, A., Zmuda, A. Gryglewski, R (1981). Role of prostaglandins in the formation of aspirin induced gastric ulcers. *Gastroenterology.* 80(1): 4-9.
- Konturek, S.J., Brzozowski, T., Majka, J., et al (1993). Fibroblast growth factor in gastroprotection and ulcer healing: interaction with sucralfate. *Gut.* 34:881-887.
- Konturek, S.J., Piastucki, I., Brzozowski, T., Radecki, T., Dembihska-Kiec, A., Amuda, A., Gryglewski, R (1981). Role of Prostaglandins in the Formation of Aspirin-Induced Gastric Ulcers. *Gastroenterology.* 80(1): 4-9
- Krystel-Whittemore, M., Dileepan, K.N. Wood, J.G (2016). Mast Cell: A Multi-Functional Master Cell. *Front. Immunol.* 6:620. doi: 10.3389/fimmu.2015.00620
- Kubes, P., Kanwar, S (1994). Histamine induces leukocyte rolling in post-capillary venules. A P-selectin-mediated event. *J Immunol.* 152(7):3570-7
- Laine, L., Taukeuchi, K., Tarnawski, A (2008). Gastric mucosal defence and cyto- protection: bench to bedside. *Gastroenterology.* 135 (1): 41-60
- Lee, P.C., Salapongse, A.N., Bragton, G.A., Shears, L.I., Watkins, S.C., Edington, H.D. Billair, T.R.(1999). Impaired wound healing and angiogenesis in eNOS –deficient mice. *Am. J Physiol. Heart. Cir.* 277:H1600-H1609
- Linder, B.L., Chernoff, A., Kaplan, K.L., Goodman, D.S (1979). Release of platelet-derived growth factor from human platelet by arachidonic acid. *Proc. Natl. Acad. Sci. U.S.A.* 76(8): 4107-11 doi:10.1073/pnas.76.8.4107
- Luna, L (1968). *Manual of Histologic Staining Methods from the Armed Forces Institute of Pathology (AFIP), 3rd Ed, pp 162-163, New York: Blakiston Division McGraw-Hill, NY.*
- Ma, L., Wallace, J.L (2000). Endothelial nitric oxide synthase modulates gastric ulcer healing in rats. *American Journal of Physiology: Gastrointestinal and Liver Physiology.* 279(2): G341-G346, ISSN 0193-1857.
- Maggs, J.L., Tingle, M.D., Kitteringham, N.R., Park, B.K (1988). Drugprotein conjugates–XIV. Mechanisms of formation of proteinylating intermediates from amodiaquine, a myelotoxin and hepatotoxin in man. *Biochem Pharmacol.* 37(2):303-311
- Malfertheiner, P., Stanghellini, V., Galmiche, J., Jones, R.H (2001). Managing the dyspeptic patient—an interactive discussion. *Aliment. Pharmacol. Therap.* 15: 14-19
- Malhotra, K., Salmon, D., Bras, J.L., Vilde, J.L (1990). Potentiation of Chloroquine activity against plasmodium falciparum by the peroxidase- Hydrogen peroxide system. *Antimicrob Agents and Chemother.* 34(10): 1981-1985 SC
- Marks, R.M., Roche, W.R., Czerniecki, M., Penny, R., Nelson, D.S (1986). Mast cell granules cause proliferation of human microvascular endothelial cells. *Laboratory Invest.* 55: 289–94.
- Nakajima, S., Arizono, N., Hattori, T., Bamba, T (1996). Increase in mucosal and connective tissue-type mast cells in the stomach with acetic acid-induced ulcer in rat. *APMIS*1996;
- Nilesh, P., Babre, P., Debnath, S., Manjunath, Y.S., Parameshwar, P., Wankhede, S.V Hairprasath, K (2010). Antioxidant potential of hydroalcoholic extract of *Barringtonia acutangula* Linn roots on streptomycin induced diabetic rats. *Int J. Pharm. Sci.* 2(4): 201- 20
- Ng, M.F.Y (2010). The role of mast cells in wound healing. *International wound journal.* 7(1): 55-61
- Nunes, Q. M., Li, Y., Sun, C., Kinnunen, T. K., Fernig, D. G (2016). Fibroblast growth factors as tissue repair and

- regeneration therapeutics. Peer J. 4, e1535. <https://doi.org/10.7717/peerj.1535>
- Norrby K (2002). Mast cells and angiogenesis. *APMIS* (2002) 110(5):355–71.
- Nosten, F., van Vugt, M., Price, R (2000). Effects of artesunate-mefloquine combination on incidence of *Plasmodium falciparum* malaria and 116 mefloquine resistance in western Thailand: a prospective study. *Lancet*. 356 (9226): 297–302.
- Okabe, S., Amagase, K., Takeuchi, K (2010). Acetic acid ulcer model. *Gastroenterol*. 17: 165-168.
- Okita, K., Karita, M., Nakanishi, N. and Takemoto, T (1991). Role of epidermal growth factor in protection and repair of gastric mucosal injury. *J. Clin. Gastroenterol*. 13 (Suppl. 1): S103-108.
- Olaleye, S.B., Elegbe, R.A (2005): Acid secretion in isolated and intact stomach of thyroidectomised and thyroxine-treated mice. *The Tropical Journal of Health Sciences*. 12 (2): 35 – 39.
- Olaleye, S.B., Ajeigbe, K.O (2009). Attenuation of experimental gastric ulceration by Sulfadoxine-pyrimethamine in albino rats. *J. Med. Sci*. 9(2): 87-92.
- Olliaro, P., Taylor, W (2005). International artemisinin study group. Artesunate combination treatment of malaria: Meta-analysis. *Lancet*. 363: 9-17
- Omayone, T.P., Salami, A.T., Oluwole, F.S., Olaleye, S.B (2016). Gastroprotective effects of vanadium in rats- the roles of gastric acid and nitric oxide. *Journal of African Association of Physiological Sciences*. 4(1): 32-40.
- Onasanwo, S.A., Singh, N., Saba, A.B., Oyagbemi, A.A., Oridupa, O.A., Palit, G (2011). Anti-ulcerogenic and in vitro antioxidant activities of *Lagenaria breviflora* (LB) whole fruit ethanolic extract in laboratory animals. *Phcog Res*. 3:2-8.
- Panés, J., Perry, M., Granger, D.N (1999). Leukocyte-endothelial cell adhesion: avenues for therapeutic intervention. *Br J Pharmacol*. 126 (3):537-550. doi:10.1038/sj.bjp.0702328
- Panés, J., Granger, D.N (1998). Leukocyte-endothelial cell interactions: molecular mechanisms and implications in gastrointestinal disease. *Gastroenterology*. 114:1066–1090.
- Park, J., Choi, K., Jeong, E., Kwon, D., Benveniste, E. N., Choi, C (2004). Reactive oxygen species mediate chloroquine induced expression of chemokines by human astroglial cells. *Glia*. 47(1): 9-20.
- Pique, J.M., Whittle, B.J., Esplugues, J.V (1989). The vasodilator role of endogenous nitric oxide in the rat microcirculation. *Eur J Pharmacol*. 174: 293-296.
- Pique, J. M., Esplugues, J. V., Whittle, B. J. R (1992). Endogenous Nitric Oxide as a Mediator of Gastric Mucosal Vasodilatation During Acid Secretion. *Gastroenterology*. 102: 168-174.
- Price, (2000): Effect of artesunate – mefloquine combination on the incidence of *Plasmodium falciparum* and mefloquine resistance in western Thailand; a prospective study. *Lancet*. 356: 297-302
- Qing-Ping, Z., Na, X., Pei, W., Xue-Qin, Y., Li-Xiang, Z., Xiao-Xia, G., Ping-Zu, Z., Frank, Q (2011). Artesunate potentiates antibiotics by inactivating heme-harboring bacterial nitric oxide synthase and catalase. *BMC Research Notes*. 4: 223
- Qu, Z., Kayton, R.J., Ahmadi, P., Liebler, J.M., Powers, M.R., Planck, S.R., et al. (1998). Ultrastructural immunolocalization of basic fibroblast growth factor in mast cell secretory granules: Morphological evidence for bFGF release through degradation. *The Journal of Histochemistry and Cytochemistry*. 46: 1119–1128
- Radziwon-Balicka, A., Moncada de la Rosa, C., Jurasz, P (2012). Platelet-associated angiogenesis regulating factors: a pharmacological perspective. *Canadian Journal of Physiology and Pharmacology*. 90(6), 679–688. doi:10.1139/y2012-036
- Raji, Y., Osonuga, O.A., Olaleye, S.B., Adedokun, K.I., Akinsomisoye, O.S., Mewoyeka, O.O (2006). Comparative Activities of Chloroquine, Mefloquine and Sulphadoxine-pyrimethamine on in vivo and ex vivo Male Reproductive Functions in Mammalian Models. *Journal of Medical Sciences*. 6: 410-415.
- Ribatti, D (2018). The Staining of Mast Cell. *Int Arch Allergy Immunol*. 176:55–60 DOI: 10.1159/000487538
- Ribatti, D, Crivellato, E (2012). Mast cells, angiogenesis, and tumour growth. *Biochimica et Biophysica Acta* 1822: 2–8.
- Ricciotti, E., FitzGerald, G. A (2011). Prostaglandins and inflammation. *Arteriosclerosis, thrombosis, and vascular biology*. 31(5), 986–1000. <https://doi.org/10.1161/ATVBAHA.110.207449>
- Salami, A.T., Ndukauba, N.G., Iyiola, T.O., Agbola, O.F., Oluwole, F.S., Olaleye, S.B (2014). Gastroprotective properties of manganese chloride on acetic acid induced ulcer in wistar rats. *African Journal of Biomedical Research*. 17(2): 101- 108.
- Salami, A.T., Odukanmi, A.O., Duduyemi, B.M., Ajeigbe, K.O (2016). Chloroquine Delays Healing of Acetic Acid-Induced Mucosal Damage in the Rat Stomach. *Archives of Basic and Applied Medicine*. 4: 129-135
- Salami, A.T., Odukanmi, A.O., Faniyan, O.F., Omayone, T.P., Olaleye, S.B (2018). Seeds of *Buchholzia coriacea* in diet mitigates ischemic reperfusion induced gastric ulceration in experimental rats. *Journal of Dietary Supplementation*. 15(6): 842-859.
- Salami, A.T., Adebimpe, M.A., Olagoke, O.C., Iyiola, T.O., Olaleye, S.B (2020). Potassium bromate cytotoxicity in the Wistar rat model of chronic gastric ulcers: Possible reversal by protocatechuic acid. *Journal of Food Biochemistry*. 44(12), e13501
- Schmassmann, A., Tarnawski, A., Peskar, B.M., Varga, L., Flogerzi, B., Halter, F (1995). Influence of acid and angiogenesis on kinetics of gastric ulcer healing in rats: interaction with indomethacin. *Am J Physiol*. 268(2 Pt 1):G276-85. doi: 10.1152/ajpgi.1995.268.2.G276. PMID: 7532364.
- Seabra, A.B., Justo, G.Z., Haddad, P.S (2015). State of the art, challenges and perspectives in the design of nitric oxide-releasing polymeric nanomaterials for biomedical applications. *Biotechnol Adv*. 33(6 Pt 3):1370–1379.
- Searles, C.D., Miwa, Y., Harrison, D.G., Ramasamy, S (1999). Posttranscriptional regulation of endothelial nitric oxide synthase during cell growth. *Circ Res*. 85(7):588–595.
- Segawa, K., Nakazawa, S., Tsukamoto, Y., Kobayashi, E., Yamaguchi, H., Goto, H (1985). Amino acid in gastric juice of peptic ulcer patients. *Jpn J Med*. 24(1): 34-38
- Serafin, W.E., Austen, K.F (1987). Current concepts: Mediators of immediate hypersensitivity reactions. *New Engl J Med*. 317: 30–4.
- Sha, J., Li, X.L., Zhu, M.H., Yang, A.P., Chen, L (2013). Effect of nesfatin-1 on gastric acid secretion in rats. *World Chin J Dig*. 21(16):1473–9.
- Slaba, I., Wang, J., Kolaczowska, E., McDonald, B., Lee, W.Y., Kubes, P (2015). Imaging the dynamic platelet-neutrophil response in sterile liver injury and repair in mice. *Hepatology*. 62(05): 1593–1605
- Stocker, T.J., Ishikawa-Ankerhold, H., Massberg, S., Schulz, C (2017). Small but mighty: Platelets as central effectors of host defense. *Thromb Haemost*. 117(4):651-661. doi: 10.1160/TH16-12-0921. Epub 2017 Feb 16. PMID: 28203681.
- Strobe, S., Miller, H.R.P., Ferguson, A (1981). Human intestinal mucosal mast cells: evaluation of fixation and staining techniques. *J Clin Pathol*. 34: 851-858

- Suzuki, H., Nishizawa, T., Tsugawa, H., Mogami, S., Hibi, T (2012). Roles of oxidative stress in stomach disorders. *Journal of clinical biochemistry and nutrition*. 50(1), 35–39. <https://doi.org/10.3164/jcbrn.11-115SR>
- Szabó, S (1984). Role of sulfhydryls and early vascular lesions in gastric mucosal injury. *Acta Physiol Hung*. 64(3-4):203-14. PMID: 6532115.
- Tarnawski, A (2005). Cellular and molecular mechanism of gastrointestinal ulcer healing. *Dig. Dis. Sci*. 50(1): S24-S33
- Theoharides, T.C., Alysandratos, K.D., Angelidou, A., Delivanis, D.A., Sismanopoulos, N., Zhang, B., Asadi, S., Vasiadi, M., Weng, Z., Miniati, A., Kalogeromitros, D (2012). Mast cells and inflammation. *Biochim Biophys Acta*. 1822(1):21-33. doi: 10.1016/j.bbdis.2010.12.014. Epub 2010 Dec 23. PMID: 21185371; PMCID: PMC3318920.
- Thomas, J. S., Hellen, I-A., Steffen, M., Christian, S (2017). Small but mighty: Platelets as central effectors of host defense. *Thromb Haemost*. 117(4):651-661.
- Thomas, S.R., Chen, K., Keaney, J.F. Jr. (2002). Hydrogen peroxide activates endothelial nitric-oxide synthase through coordinated phosphorylation and dephosphorylation via a phosphoinositide 3-kinase-dependent signalling pathway. *J Biol Chem*. 277(8):6017–6024.
- Turner, F.P., Brum, V.C., Bilodeau, E.G (1977). Incorporation of <sup>35</sup>S-methionine by the rat with steroid ulceration. *J Maine Med Assoc*. 68: 227-43.
- Uspenskiĭ, V. M., Grinevich, V. B (1980). Tushnye kletki kak kriterii aktivnosti reparativnykh protsessov pri iazvnykh porazheniiakh zheludka Mast cells as a criterion of repair process activity in ulcerative stomach lesions *Arkh Patol*. 42(6):14-9. Russian. PMID: 7417008
- Varshney, R., Kale, R.K (1990). Effects of Calmodulin Antagonist on Radiation-induced Lipid Peroxidation in Microsomes. *Int. J. Rad. Biol*. 58: 733-743
- Vatankhah Nasibeh, Younes Jahangiri, Gregory J Landry, Robert B McLafferty, Nabil J Alkayed, Gregory L Moneta, Amir F Azarbal (2017): Predictive value of neutrophil-to-lymphocyte ratio in diabetic wound healing. *J Vasc Surg*. 65(2):478-483. doi: 10.1016/j.jvs.2016.08.108.
- Von Hundelshausen, P., Weber, K.S., Huo, Y., Proudfoot, A.E., Nelson, P.J., Ley, K., Weber, (2001). RANTES deposition by platelets triggers monocyte arrest on inflamed and atherosclerotic endothelium. *Circulation*. 103: 1718-1720
- Wall, I.B., Moseley, R., Baird, D.M., Kipling, D., Giles, P., Laffafian, I., Price, P.E., Thomas, D.W., Stephens, P. (2008). Fibroblast dysfunction is a key factor in the non-healing of chronic venous leg ulcers. *J Invest Dermatol*. 128(10):2526-40. doi: 10.1038/jid.2008.114. Epub 2008 May 1. PMID: 18449211.
- Weller, K., Foitzik, K., Paus, R., Syska, W., Maurer, M (2006). Mast cells are required for normal healing of skin wounds in mice. *FASEB J* 20:2366–2368
- Werther, J.N (2000). The gastric mucosal barrier. *The Mount Sinai n Journal of Medicine*. 67(1).
- White, N.J (2004). Antimalaria drug resistance. *J. Clin. Investigat*. 113: 1084-1092.
- Wolff, S.P (1994). Ferrous ion oxidation in presence of ferric ion indicator xylenol orange for measurement of hydroperoxides. *Methods in Enzymology*. 233: 182-189
- Zibima, S.B., Oniso, J.I., Wasini, K.B et.al. (2020). Prevalence trends and associated modifiable risk factors of peptic ulcer disease among students in a university community south-south Nigeria. *Int J Health Sci Res*. 10(6):97-105

#### Acknowledgement

*The publication of this issue of Archives of Basic and Applied Medicine was funded by the University of Ibadan Medical Education Partnership Initiative Junior Faculty Research Training Program (UI-MEPI-J), Award Number D43TW010140 from the Fogarty International Centre. The content is solely the responsibility of the authors and does not necessarily represent the official views of Fogarty International Centre or the National Institute of Health.*